

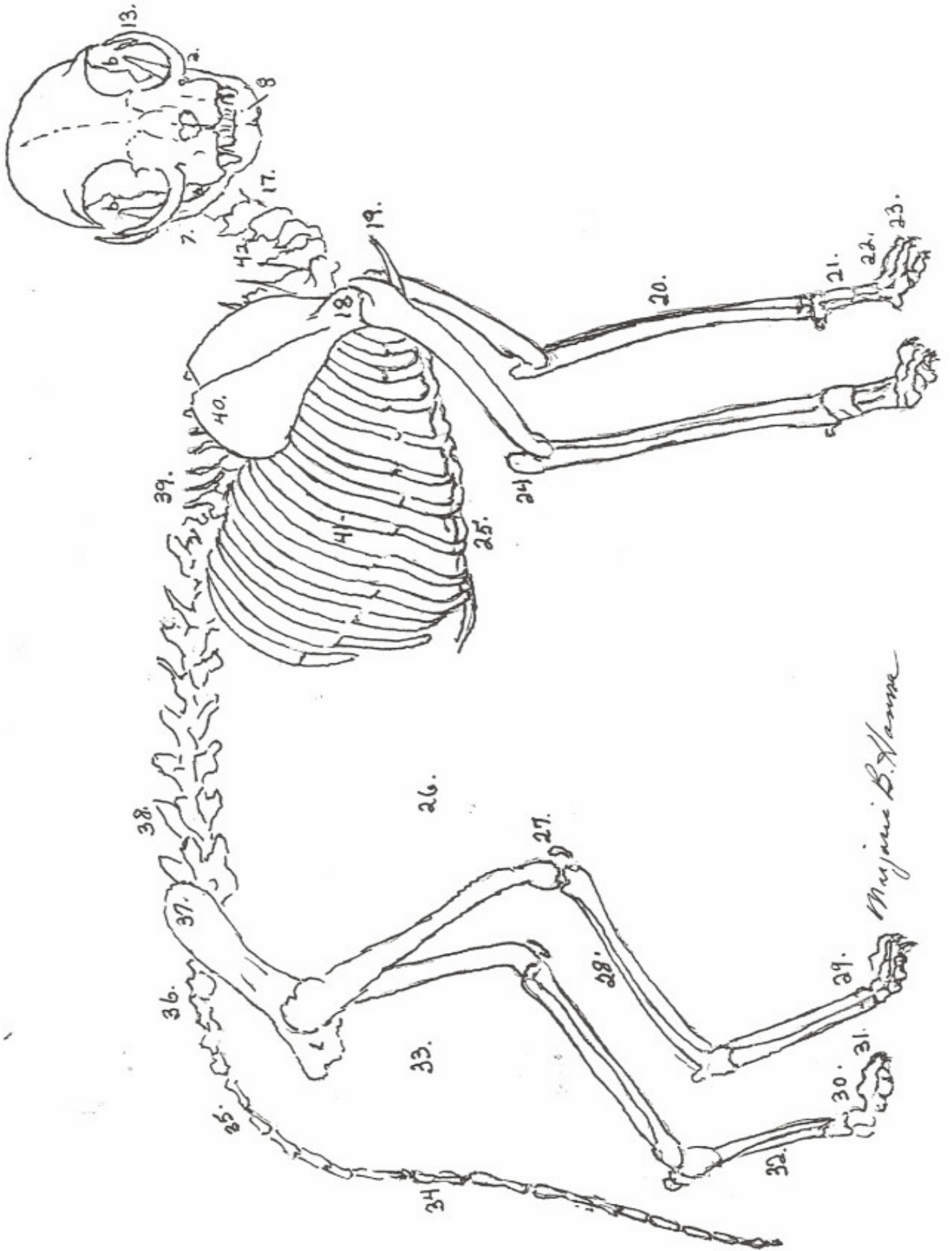
# TERMINOLOGY AS IT APPLIES TO TICA BREED STANDARDS

Interpretation by Marge Hanna

1. Nose: The area, with its underlying cartilage, from the top edge of the nose leather up to the bottom of the bridge of the nose.
2. Bridge of the Nose: The bony area on the top of the nose below the eyes.
3. Area from the bridge of the nose to the brow line> Examples can be:
  - a. A straight level plane
  - b. A gentle rise
  - c. A slightly concave rise or dip
  - d. A stop or change of direction; may be very slight or pronounced, or
  - e. A break or indentation at about eye level or between the eyes
4. Brow line: The protective bony area across the face at the top of the eye aperture
5. Forehead: The frontal area between the brow line and the inside bottom edge of the ear, generally about a thumb's width above the brow line on an average adult domestic feline
6. Top Head area to Occiput: The uppermost boning of the skull to just before the head turns onto the upper neck. Can be viewed best by gently holding the ears along the side of the head and looking across the head while viewing the profile.
7. Jaw line: The line from the front tip of the chin back along the mandible (lower jaw) to the back angular point (a) of the jaw.
8. Chin: The part of the jaw containing the lower incisors and canines. Should be padded to some extent in all breeds and all lower teeth shall be in correct alignment with upper teeth and shall be neither:
  - a. Overshot: The upper jaw, and teeth, protruding in front of lower jaw and teeth, nor
  - b. Undershot: The lower jaw and teeth protruding out in front of the upper teeth and jaw, nor
  - c. Wry mouthed: Viewed from the front, the mouth parts, either upper or lower and sometimes both, are abnormally twisted or bent, either down or to one side. The lower jaw aligned outside the line or to the side of the upper mouth. This is the worst of the abnormal bites.
9. Chin and nose profile: A straight line, viewed from the side, from end of nose (11) to the chin (8). In some cases allowance should be taken into account for the soft upper lip (9) appearing to be outside the line.
10. Muzzle: The lower area of the face, or head, from under eye aperture to the lower end of the head or nose, containing the jaw, lips, incisors and canines, the whisker pads and nasal area and nose leather.
11. Nose Leather: The bare nose pad that contains the nostrils.
12. Muzzle/Whisker Break or Whisker Pinch: The change of direction between the muzzle and the lower cheekbones under the eye or at the side of the face.
13. Cheekbone: The arched bone that starts under the eye area (malar) and curves up and out past the eye aperture (zygomatic arch) to slightly past the line of the angular point (a) of the jaw, protecting both the eye as well as keeping the top point (b) of the jaw that extends into the skull area (behind the eye orbit) in line. In most breeds the angle of the eye aperture follows the angle of the cheekbone.
14. Whisker Pads: The muscular pads on the side of the muzzle that cover and protect the nasal and upper canine area and control the movement of the whiskers.
15. Profile: The lines, viewed from the side, from the tip of the nose (1) up to the top of the head (6), from the tip of the nose (11) to the chin (8) and back along the jaw line (7).
16. Wedge: The line, viewed from the front, from the lower muzzle, past the canines (10), up along the side of the cheek (13) to the outer bottom edge of the ear (16). In some breeds the ears are to be a continuation of the wedge.
17. Upper throat or hyoid area: The top of the neck where it meets and turns into the soft under-part of the jaw.
18. Front point of the Shoulder: The joint at the upper end of the humerus (upper arm) where it fits into the lower structure of the scapula (shoulder blade).
19. Anterior (front end) of the sternum: The sternum runs from the anterior (19) back and under the body between the front legs and along the chest to (25) the lower sternum.

20. Long bones of the front legs (two): the radius and the ulna that join at the lower end of the humerus at the elbow.
21. Carpels: The tiny bones that correspond with the human wrist at the lower end of the radius and the ulna.
  - a. Carpal pad: The small pad on the back of the carpal area. Has no corresponding feature in the human.
22. Metacarpal: The small longish bones above the toes that correspond to the bones on the top of a human hand.
23. Toes (phalanges) of the front paw (five): Four are jointed to a metacarpal at the top of the paw (third joint) and ending in a claw system at the front of the first phalange or digit. The fifth metacarpal bone on the inside part of the "hand" is shorter and supports the fifth toe or "dew claw". Corresponds to the human thumb.
24. Elbow: The joint of the lower end of the humerus and the top of the radius and ulna.
25. Sternum or breast plate: With the exception of the thirteenth, or floating rib, the sternum anchors the lower ends (cartilage) of the ribs and supports the rib cage.
26. Flank: Muscular lower part of the body between the last rib and the knee, or thigh areas on either side of the body. Depth of flank is measured from this area (a) to the top of the torso (b).
27. Knee: The joint of lower end of the femur and the top of the long bones of the back of the leg (two), the tibia and the fibula. The joint is protected by a small bone, attached by cartilage to upper and lower boning, called the knee cap or patella.
28. Thigh: The heavily muscled area covering the femur. The thigh and the rump (33) are normally the heaviest part of any feline.
29. Tarsals: The small bones that correspond with the human ankle at the lower end of the tibia and fibula.
30. Metatarsals: The small longish bones above the toes on the back leg that correspond with the bones of the flat part of a human foot.
31. Toes (phalanges) of the back paw (four): Each structured as in the front paws. (23) The fifth toe on the back paw no longer exists.
32. Hock: The flat area on the back side of the metatarsals from the point of the heel down to the back of the back paw. Corresponds with the arch on the bottom and the heel of the human foot.
33. Rump: The muscular rear end of the torso covering the back tip of the pelvic structure.
34. Tail or caudal vertebrae: Normally has 14 to 28 tapering vertebrae.
35. Base of the tail: The area where the tail meets the body directly in line above the rump and behind the sacrum.
36. Croup: The area from the base of the tail (35) to the top of the hip vertebrae.
37. Hip bone (ilium): The top of the hip bone lies in front of the hip vertebrae (3) at the sacrum. The lower end holds the top of the femur as a ball and joint system at the pubic girdle.
38. Back or lumbar region of the back bones (7 vertebrae) between the top of the hip (37) to the top of the last rib just behind the shoulder blade. Extremely flexible.
39. Thoracic vertebrae: Upper chest, 13 vertebrae go from the lumbar vertebrae, between the shoulder blades, at the withers, to the seven cervical, or neck, vertebrae and support the top 13 sets of rib bones.
40. Shoulder blade or scapula: Upper part attached only by muscles and tendons at the thoracic region. Lower end is a ball and cup joint system at the top of the humerus.
41. Rib cage: Bowed out and slightly expandable, rib (thirteen) are bone where each is joined at the back bone at the thirteen thoracic vertebrae. Approximately three quarters of the way down each rib they are attached to the cartilage part of each rib which extend slightly forward and are attached to sternum, at the lower part of the torso.
42. Neck bones or cervical vertebrae (seven) support the skull and mandible structure.





Mujibur B. Hossain

